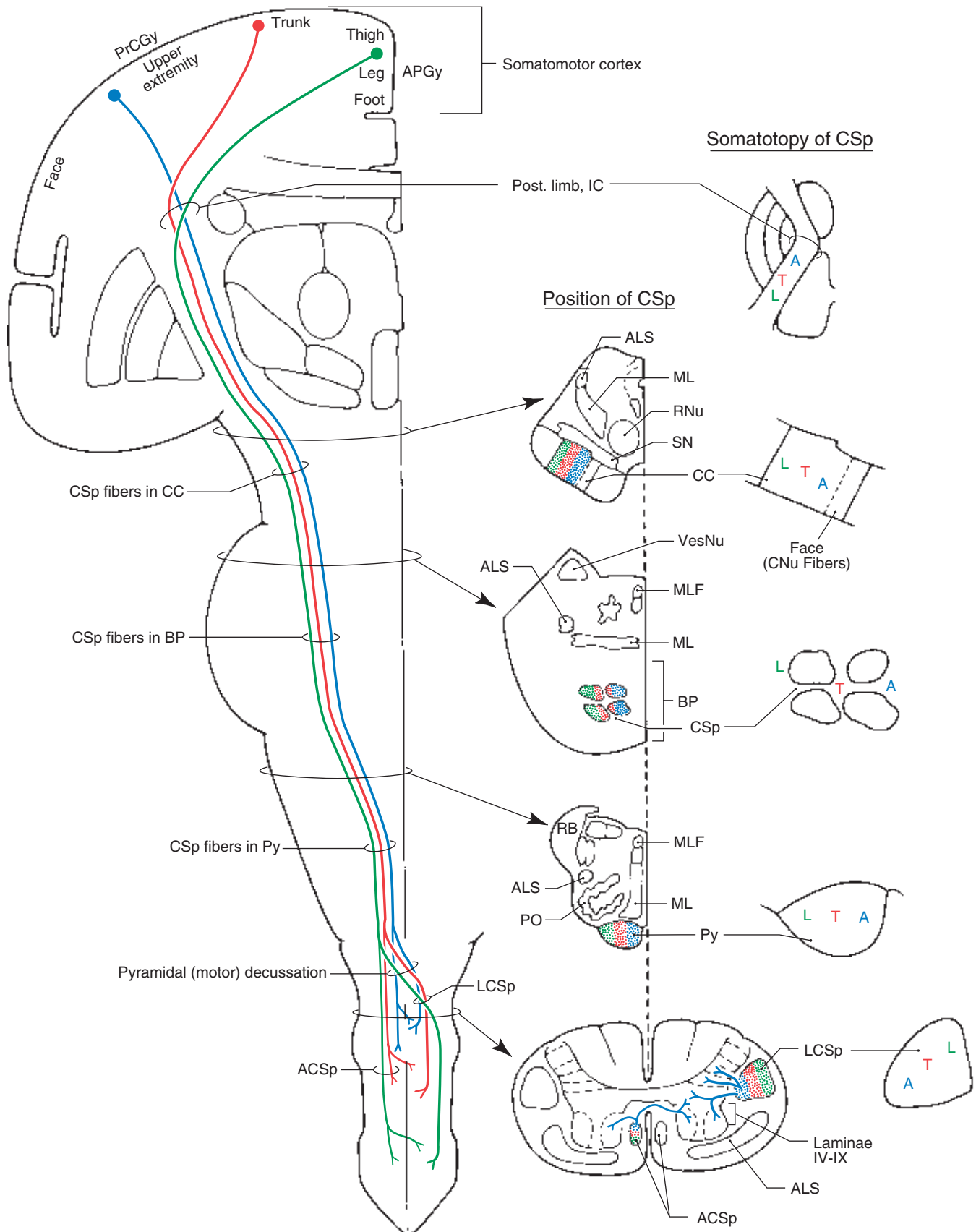


## Corticospinal Tracts



Corticonuclear (Corticobulbar) Fibers

**7-11** The origin, course, and distribution of corticonuclear (corticobulbar) fibers to brainstem motor nuclei. These fibers influence—either directly or through neurons in the immediately adjacent reticular formation—the motor nuclei of oculomotor, trochlear, trigeminal, abducens, facial, glossopharyngeal and vagus (both via nucleus ambiguus), spinal accessory, and hypoglossal nerves.

Corticonuclear (corticobulbar) fibers arise in the frontal eye fields (areas 6 and 8 in caudal portions of the middle frontal gyrus), the precen-tral gyrus (somatomotor cortex, area 4), and some originate from the postcentral gyrus (areas 3,1, 2). Fibers from area 4 occupy the genu of the internal capsule, but those from the frontal eye fields (areas 8,6) may traverse caudal portions of the anterior limb, and some (from areas 3,1,2), may occupy the most rostral portions of the posterior limb. Fibers that arise in areas 8 and 6 terminate in the *rostral interstitial nucleus of the medial longitudinal fasciculus* (*vertical gaze center*) and in the *paramedian pontine reticular formation* (*horizontal gaze center*); these areas, in turn, project respectively to the IIIrd and IVth, and to the VIth nuclei. Fibers from area 4 terminate in, or adjacent to, cranial nerve motor nuclei ex-cluding those of III, IV, and VI.

Although not illustrated here, the superior colliculus receives cor-tical input from area 8 and from the parietal eye field (area 7) and also projects to the riMLF and PPRF. In addition, it is important to note that descending cortical fibers (many arising in areas 3, 1, 2) project to sensory relay nuclei of some cranial nerves and to other sensory relay nuclei in the brainstem, such as those of the posterior column system.

**Neurotransmitters:** Glutamate (+) is found in many corticofugal axons that directly innervate cranial nerve motor nuclei and in those fibers that terminate near (indirect), but not in, the various mo-tor nuclei.

**Clinical Correlations:** Lesions involving the motor cortex (as in cerebral artery occlusion) or the internal capsule (as in *lacunar strokes* or occlusion of lenticulostriate branches of M<sub>1</sub>) give rise to a con-tralateral *hemiplegia* of the arm and leg (corticospinal fiber involve-ment) coupled with certain cranial nerve signs. Strictly cortical lesions

may produce a transient *gaze palsy* in which the eyes deviate toward the lesioned side and away from the side of the hemiplegia. In addition to a contralateral *hemiplegia*, common cranial nerve findings in capsular le-sions may include 1) deviation of the tongue toward the side of the weakness and away from the side of the lesion when protruded and 2) paralysis of facial muscles on the contralateral lower half of the face (*central facial palsy*). This reflects the fact that corticonuclear (cortico-bulbar) fibers to genioglossus motor neurons and to facial motor neu-rons serving the lower face are primarily crossed. Interruption of cor-ticonuclear fibers to the nucleus ambiguus may result in weakness of palatal muscles contralateral to the lesion; the uvula will deviate to-wards the ipsilateral (lesioned) side on attempted phonation. In addi-tion, a lesion involving corticonuclear fibers to the accessory nucleus may result in drooping of the ipsilateral shoulder (or an inability to el-evate the shoulder against resistance) due to trapezius weakness, and difficulty in turning the head (against resistance) to the contralateral side due to weakness of the sternocleidomastoid muscle. In contrast to the *alternating hemiplegia* seen in some brainstem lesions, hemisphere lesions result in spinal and cranial nerve deficits that are generally, but not exclusively, contralateral to the cerebral injury.

Brainstem lesions, especially in the midbrain or pons, may result in the following: 1) *vertical gaze palsies* (midbrain), 2) the *Parinaud syn-drome*—paralysis of upward gaze (tumors in area of pineal), 3) *internu-clear ophthalmoplegia* (lesion in MLF between motor nuclei of III and VI), 4) *horizontal gaze palsies* (lesion in PPRF), or 5) *the one-and-a-half syndrome*. In the latter case, the lesion is adjacent to the midline and in-volves the abducens nucleus and adjacent PPRF, internuclear fibers from the ipsilateral abducens that are crossing to enter the contralat-eral MLF, and internuclear fibers from the contralateral abducens nu-cleus that cross to enter the MLF on the ipsilateral (lesioned) side. The result is a loss of ipsilateral abduction (lateral rectus) and adduction (medial rectus, the “one”) and a contralateral loss of adduction (medial rectus, the “half”); the only remaining horizontal movement is con-tralateral abduction via the intact abducens motor neurons.

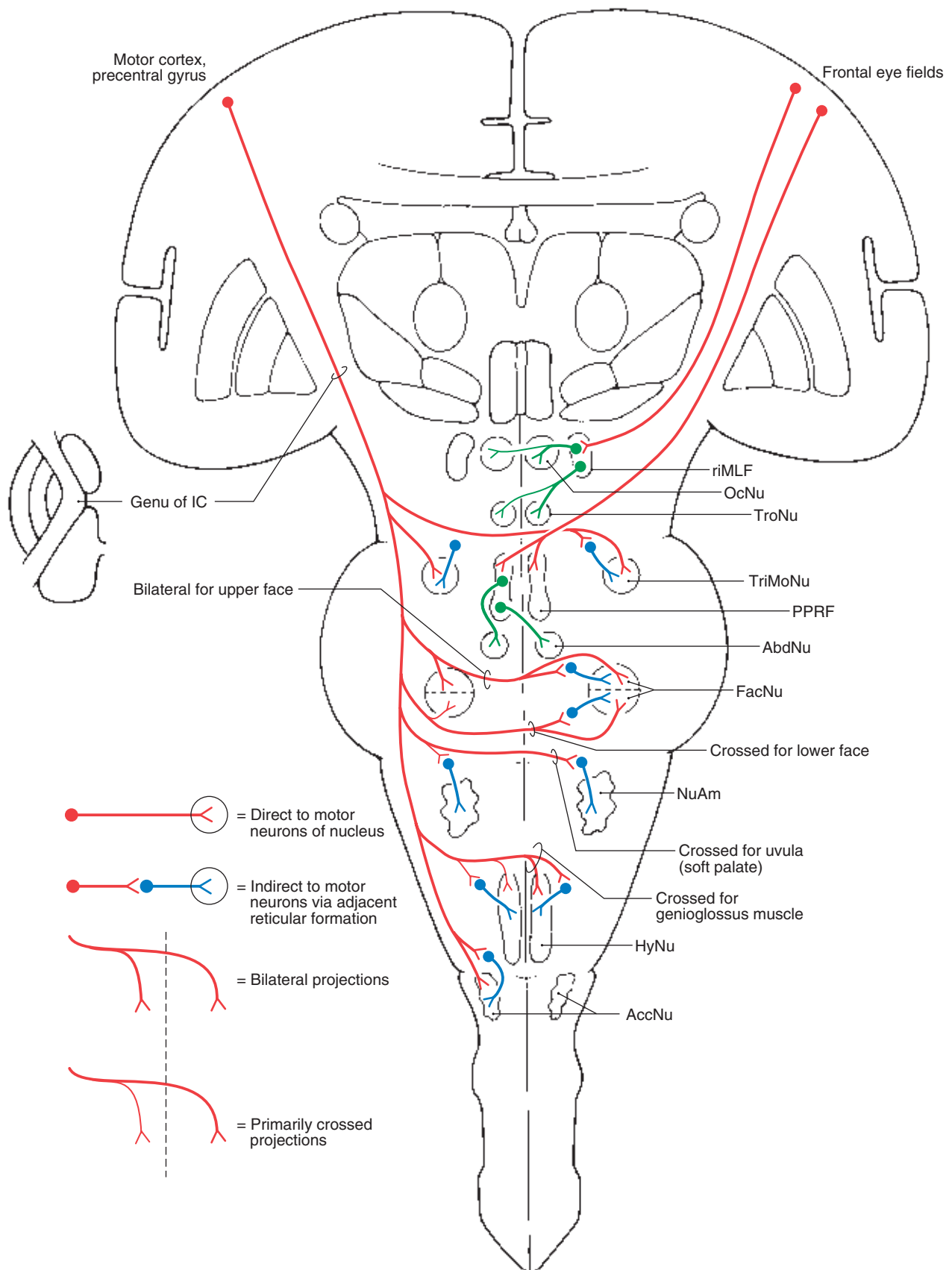
Abbreviations

|              |  |                |  |
|--------------|--|----------------|--|
| <b>AbdNu</b> | Abducens nucleus                         | <b>OcNu</b>    | Oculomotor nucleus   |
| <b>AccNu</b> | Accessory nucleus (spinal accessory nu.) | <b>PPRF</b>    | Paramedian pontine reticular formation                             |
| <b>FacNu</b> | Facial nucleus                           | <b>riMLF</b>   | Rostral interstitial nucleus of the medial longitudinal fasciculus |
| <b>HyNu</b>  | Hypoglossal nucleus                      | <b>TriMoNu</b> | Trigeminal motor nucleus   |
| <b>IC</b>    | Internal capsule                         | <b>TroNu</b>   | Trochlear nucleus  |
| <b>NuAm</b>  | Nucleus ambiguus                         |                |  |

Review of Blood Supply to Cranial Nerve Motor Nuclei

| STRUCTURES                    | ARTERIES   |
|-------------------------------|--|
| <b>OcNu</b> and <b>EWNu</b>   | paramedian branches of basilar bifurcation and medial branches of posterior cerebral and posterior communicating (see Figure 5-27) |
| <b>TriMoNu</b>                | long circumferential branches of basilar (see Figure 5-21)   |
| <b>AbdNu</b> and <b>FacNu</b> | long circumferential branches of basilar (see Figure 5-21)   |
| <b>NuAm</b>                   | posterior inferior cerebellar (see Figure 5-14)  |
| <b>HyNu</b>                   | anterior spinal (see Figure 5-14)  |

## Corticonuclear (Corticobulbar) Fibers



Tectospinal and Reticulospinal Tracts

**7-12** The origin, course, position in representative cross-sections of brainstem and spinal cord, and the general distribution of tectospinal and reticulospinal tracts. Tectospinal fibers originate from deeper layers of the superior colliculus, cross in the posterior (dorsal) tegmental decussation, and distribute to cervical cord levels. Several regions of cerebral cortex (e.g., frontal, parietal, temporal) project to the tectum, but the most highly organized corticotectal projections arise from the visual cortex. Pontoreticulospinal fibers (medial reticulospinal) tend to be uncrossed, while those from the medulla (bulboreticulospinal or lateral reticulospinal) are bilateral but with a pronounced ipsilateral preponderance. Corticoreticular fibers are bilateral with a slight contralateral preponderance and originate from several cortical areas.

**Neurotransmitters:** Corticotectal projections, especially those from the visual cortex, utilize glutamate (+). This substance is also present in most corticoreticular fibers. Some neurons of the gigantocellular reticular nucleus that send their axons to the spinal cord, as reticulospinal projections, contain enkephalin (–) and substance P (+). Enkephalinergic reticulospinal fibers may be part of the descend-

ing system that modulates pain transmission at the spinal level. Many reticulospinal fibers influence the activity of lower motor neurons.

**Clinical Correlations:** Isolated lesions of only tectospinal and reticulospinal fibers are essentially never seen. Tectospinal fibers project to upper cervical levels where they influence reflex movement of the head and neck. Such movements may be diminished or slowed in patients with damage to these fibers. Pontoreticulospinal (medial reticulospinal) fibers are excitatory to extensor motor neurons and to neurons innervating axial musculature; some of these fibers may also inhibit flexor motor neurons. In contrast, some bulboreticulospinal (lateral reticulospinal) fibers are primarily inhibitory to extensor motor neurons and to neurons innervating muscles of the neck and back; these fibers may also excite flexor motor neurons via interneurons. Reticulospinal (and vestibulospinal) fibers contribute to the *spasticity* that develops in patients having lesions of corticospinal fibers. These reticulospinal and vestibulospinal fibers (see Figure 7-13 on page 196) also contribute to the tonic extension of the arms and legs seen in *decerebrate rigidity* when spinal motor neurons are released from descending cortical control.

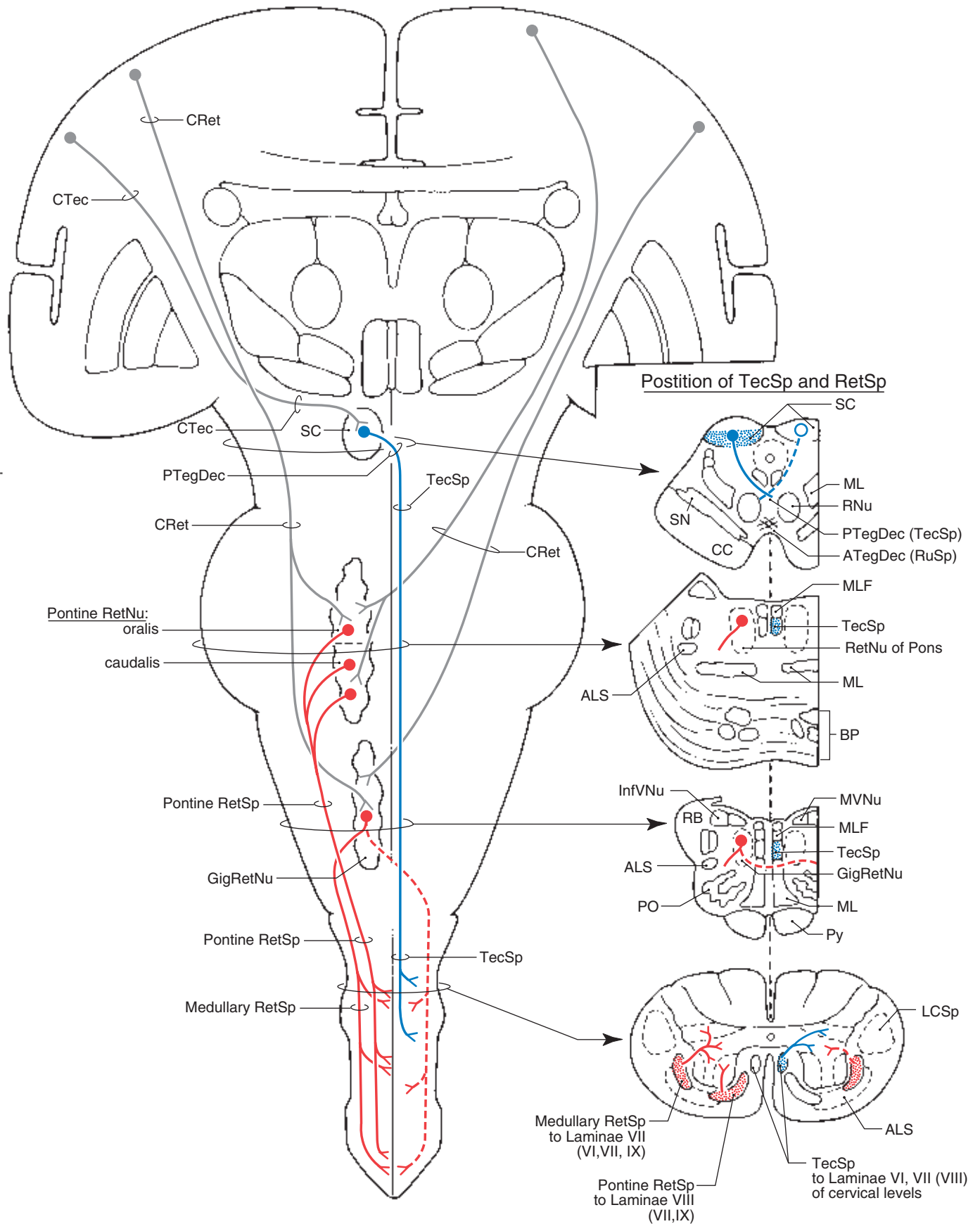
Abbreviations

|          |   |         |  |
|----------|---|---------|--|
| ALS      | Anterolateral system                                | PO      | Principal olivary nucleus                            |
| ATegDec  | Anterior tegmental decussation (rubrospinal fibers) | PTegDec | Posterior tegmental decussation (tectospinal fibers) |
| BP       | Basilar pons  | Py      | Pyramid  |
| CC       | Crus cerebri  | RB      | Restiform body                                       |
| CRet     | Corticoreticular fibers                             | RetNu   | Reticular nuclei                                     |
| CTec     | Corticotectal fibers                                | RetSp   | Reticulospinal tract(s)                              |
| GigRetNu | Gigantocellular reticular nucleus                   | RNu     | Red nucleus  |
| LCSp     | Lateral corticospinal tract                         | RuSp    | Rubrospinal tract                                    |
| ML       | Medial lemniscus                                    | SC      | Superior colliculus                                  |
| MLF      | Medial longitudinal fasciculus                      | SN      | Substantia nigra                                     |
| MVNu     | Medial vestibular nucleus                           | SpVNu   | Spinal (or inferior) vestibular nucleus              |
| OcNu     | Oculomotor nucleus                                  | TecSp   | Tectospinal tract                                    |

Review of Blood Supply to SC, Reticular Formation of Pons and Medulla, and TecSp and RetSp Tracts in Cord

| STRUCTURES                    | ARTERIES  |
|-------------------------------|---|
| SC                            | long circumferential branches (quadrigeminal branch) of posterior cerebral plus some from superior cerebellar and posterior choroidal (see Figure 5-27) |
| Pontine Reticular Formation   | long circumferential branches of basilar plus branches of superior cerebellar in rostral pons (see Figure 5-21)   |
| Medullary Reticular Formation | branches of vertebral plus paramedian branches of basilar at medulla-pons junction (see Figure 5-14)  |
| TecSp and RetSp               | branches of central artery (TecSp and Medullary RetSp); Tracts penetrating branches of arterial vasocorona (Pontine RetSp) (see Figures 5-14 and 5-6)   |

## Tectospinal and Reticulospinal Tracts



Rubrospinal and Vestibulospinal Tracts

**7-13** The origin, course, and position in representative cross-sections of brainstem and spinal cord, and the general distribution of rubrospinal and vestibulospinal tracts. Rubrospinal fibers cross in the anterior (ventral) tegmental decussation and distribute to all spinal levels although projections to cervical levels clearly predominate. Cells in dorsomedial regions of the red nucleus receive input from upper extremity areas of the motor cortex and project to cervical cord, but those in ventrolateral areas of the nucleus receive some fibers from lower extremity areas of the motor cortex and may project in sparse numbers to lumbosacral levels. The red nucleus also projects, via the central tegmental tract, to the ipsilateral inferior olivary complex (rubroolivary fibers).

Medial and lateral vestibular nuclei give rise to the medial and lateral vestibulospinal tracts, respectively. The former tract is primarily ipsilateral, projects to upper spinal levels, and is considered a component of the medial longitudinal fasciculus in the spinal cord. The latter tract is ipsilateral and somatotopically organized; fibers to lumbosacral levels originate from dorsal and caudal regions of the lateral nucleus, while those to cervical levels arise from its rostral and more ventral areas.

**Neurotransmitters:** Glutamate (+) is present in corticorubral fibers. Some lateral vestibulospinal fibers contain aspartate (+), whereas glycine (−) is present in a portion of the medial vestibulospinal projection. There are numerous gamma-aminobutyric acid (−)-containing fibers in the vestibular complex; these represent the endings of cerebellar corticovestibular fibers.

**Clinical Correlations:** Isolated injury to rubrospinal and vestibulospinal fibers is really not seen in humans. Deficits in fine distal limb movements seen in monkeys following experimental rubrospinal lesions may be present in humans. However, these deficits are overshadowed by the *hemiplegia* associated with injury to the adjacent corticospinal fibers. The contralateral tremor seen in patients with the *Claude syndrome* (a lesion of the medial midbrain) is partially related to damage to the red nucleus as well as to the adjacent cerebellothalamic fibers. These patients may also have a paucity of most eye movement on the ipsilateral side and a dilated pupil (*mydriasis*) due to concurrent damage to exiting rootlets of the oculomotor nerve.

Medial vestibulospinal fibers primarily inhibit motor neurons innervating extensors and neurons serving muscles of the back and neck. Lateral vestibulospinal fibers may inhibit some flexor motor neurons, but they mainly facilitate spinal reflexes via their excitatory influence on spinal motor neurons innervating extensors. Vestibulospinal and reticulospinal (see Figure 7-12 on page 194) fibers contribute to the *spasticity* seen in patients with damage to corticospinal fibers or to the tonic extension of the extremities in patients with *decerebrate rigidity*. In the case of decerebrate rigidity, the descending influences on spinal flexor motor neurons (corticospinal, rubrospinal) is removed; the descending brainstem influence on spinal extensor motor neurons predominates; this is augmented by excitatory spinoreticular input (via ALS) to some of the centers giving rise to reticulospinal fibers (see also Figure 7-12 on page 194).

Abbreviations

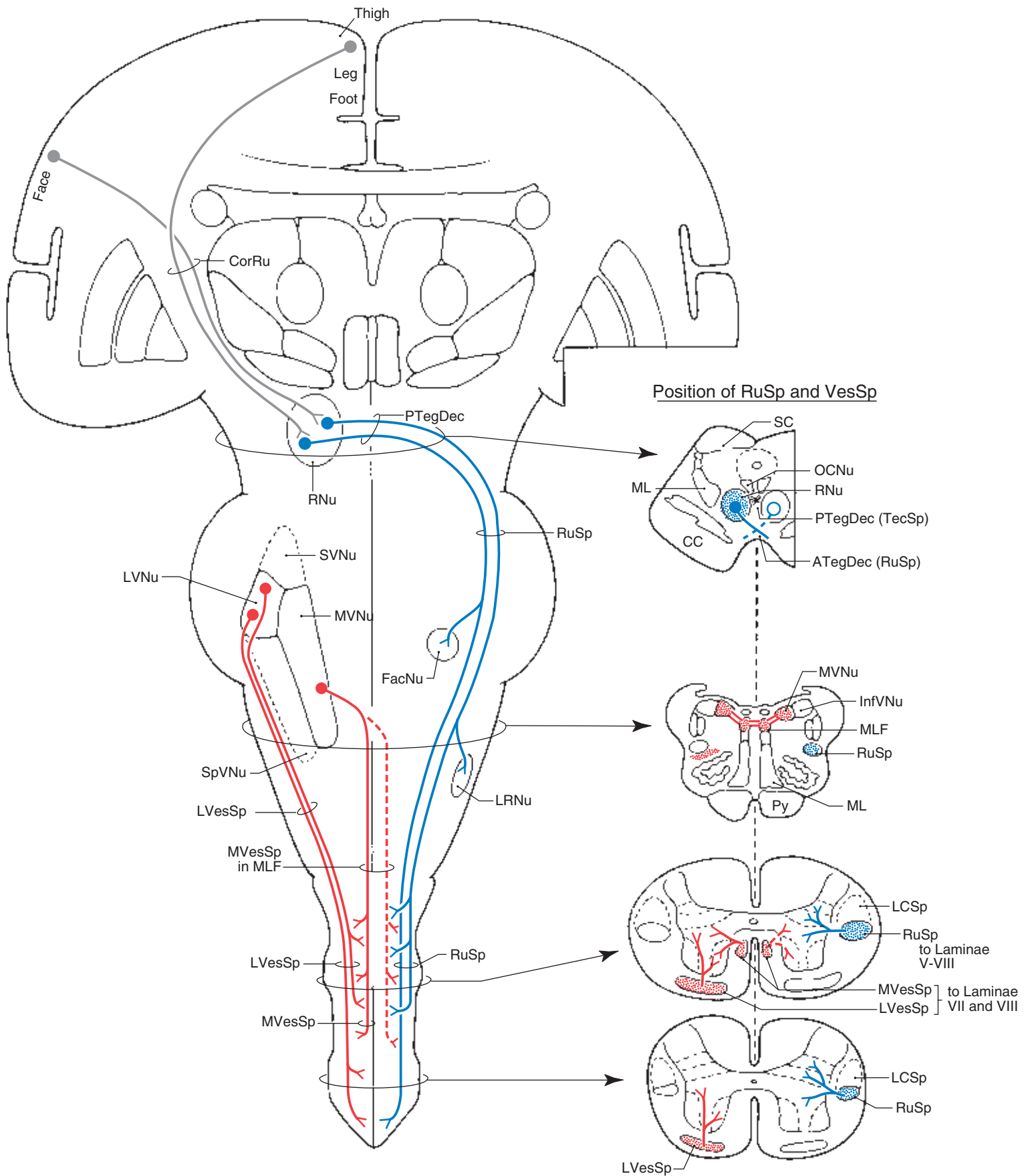
|                |   |                |  |
|----------------|---|----------------|--|
| <b>ATegDec</b> | Anterior tegmental decussation (rubrospinal fibers) | <b>MVessp</b>  | Medial vestibulospinal tract                         |
| <b>CC</b>      | Crus cerebri  | <b>MVNu</b>    | Medial vestibular nucleus                            |
| <b>CorRu</b>   | Corticorubral fibers                                | <b>OcNu</b>    | Oculomotor nucleus                                   |
| <b>FacNu</b>   | Facial nucleus                                      | <b>PTegDec</b> | Posterior tegmental decussation (tectospinal fibers) |
| <b>InfVNu</b>  | Inferior (or spinal) vestibular nucleus             | <b>Py</b>      | Pyramid  |
| <b>LCSp</b>    | Lateral corticospinal tract                         | <b>RNu</b>     | Red nucleus  |
| <b>LRNu</b>    | Lateral reticular nucleus                           | <b>RuSp</b>    | Rubrospinal tract                                    |
| <b>LVNu</b>    | Lateral vestibular nucleus                          | <b>SC</b>      | Superior colliculus                                  |
| <b>LVesSp</b>  | Lateral vestibulospinal tract                       | <b>SVNu</b>    | Superior vestibular nucleus                          |
| <b>ML</b>      | Medial lemniscus                                    | <b>TecSp</b>   | Tectospinal tract                                    |
| <b>MLF</b>     | Medial longitudinal fasciculus                      | <b>VesSp</b>   | Vestibulospinal tracts                               |

Review of Blood Supply to RNu, Vestibular Nuclei, MFL and RuSp, and Vestibulospinal Tracts in Cords

| STRUCTURES             | ARTERIES  |
|------------------------|---|
| <b>RNu</b>             | medial branches of posterior cerebral and posterior communicating plus some from short circumferential branches of posterior cerebral (see Figure 5-27) |
| Vestibular Nuclei      | posterior inferior cerebellar in medulla (see Figure 5-14) and long circumferential branches in pons (see Figure 5-21)                                  |
| <b>MLF</b>             | long circumferential branches of basilar in pons (see Figure 5-21) and anterior spinal in medulla (see Figure 5-14)                                     |
| <b>MVesSp</b>          | branches of central artery (see Figures 5-6 and 5-14)   |
| <b>LVesSp and RuSp</b> | penetrating branches of arterial vasocorona plus terminal branches of central artery (see Figure 5-6)   |



## Rubrospinal and Vestibulospinal Tracts



**7-14** Blank master drawing for motor pathways. This illustration is provided for self-evaluation of motor pathways understanding, for the instructor to expand on motor pathways not covered in this atlas, or both.



